



ELSEVIER



Autologous fat grafting to the breast for cosmetic enhancement: experience in 66 patients with long-term follow up

Dan-Ning Zheng^a, Qing-Feng Li^{a,*}, Hua Lei^a, Sheng-Wu Zheng^a, Yu-Zhi Xie^b, Qiu-Hua Xu^c, Xie Yun^a, Lee L.Q. Pu^d

^a Department of Plastic & Reconstructive Surgery, Shanghai Ninth People's Hospital, Shanghai Medical College of Jiao Tong University, Shanghai, P.R. China

^b Department of Radiology, Shanghai Ninth People's Hospital, Shanghai Medical College of Jiao Tong University, Shanghai, P.R. China

^c Department of Ultrasound, Shanghai Ninth People's Hospital, Shanghai Medical College of Jiao Tong University, Shanghai, P.R. China

^d Division of Plastic Surgery, University of California, Davis, UC Davis Medical Center, CA, USA

Received 9 August 2007; accepted 28 August 2007

KEYWORDS

Liponecrotic cyst;
Autologous fat
transplantation;
Breast augmentation;
Fat grafting;
Breast

Summary *Background:* Autologous fat grafting to the breast for cosmetic enhancement remains controversial because the efficacy and fate of fat grafting to the breast are primarily unknown. In this report, we present our retrospective study in 66 patients who underwent autologous fat grafting to the breast for various cosmetic reasons and who were followed with sonography, mammography, or magnetic resonance imaging (MRI).

Methods: Sixty-six patients who desired cosmetic enhancement of the breast for various reasons underwent autologous fat transplantation between August 2000 and March 2005 in our institution. The cosmetic outcome was assessed by the plastic surgeons as well as the patients. The imaging features of fat necrosis, cyst formation, and calcification in these patients were carefully studied and biopsies of palpable lumps were evaluated histologically.

Results: All patients were followed from 13 to 61 months with an average of 37 months. Breast cosmetic contour was significantly improved in 28 patients (42.4%), improved in 24 patients (36.4%), and not improved in 14 patients (21.2%) as judged by the plastic surgeons. Twenty-seven patients (40.9%) were very satisfied, 26 patients (39.4%) were satisfied, and 13 patients (19.7%) were unsatisfied. Eleven patients (16.7%) developed liponecrotic cysts but only two patients elected to have the breast lump surgically removed.

* Corresponding author. Address: Department of Plastic and Reconstructive Surgery, Shanghai Ninth People's Hospital, Shanghai Medical College of Jiao Tong University, 639 Zhizaoju Road, Shanghai 200011, P.R. China. Fax: +86 21 63089567.

E-mail address: liqfliq@yahoo.com.cn (Q.-F. Li).

Conclusion: Autologous fat grafting to the breast can be a useful procedure for cosmetic enhancement in many patients who desire such a procedure. Patients with breast contour deformities after removal of silicon implants were found to be the best candidates for fat grafting. The primary long-term complication is the formation of liponecrotic cysts which have characteristically benign appearances in sonography, mammography or MRI.

© 2008 British Association of Plastic, Reconstructive and Aesthetic Surgeons. Published by Elsevier Ltd. All rights reserved.

Since Bircoll first reported breast augmentation with fat injection in 1987,¹ the controversy remains in terms of the efficacy and long-term complications of autologous fat grafting to the breasts. One main concern of many plastic surgeons is the formation of a lump within the breast secondary to fat necrosis, which can mimic breast cancer both clinically and radiologically. Necrosis of the grafted fatty tissue has been reported by others in several different locations in the body.^{2–5} Inflammatory response to the fat grafts with nonfunctional components has included adipose fragments, clots, ruptured cells, collagen septa, and free oil substances.⁶ If fat grafts are injected in bulk into a target area, the centre of the grafted material may become necrotic if vascularisation fails to occur within the bulk of the fat grafts.⁷

Recent development and refinement of the technique in fat grafting have made it possible to decrease the amount of fat necrosis after autologous fat transplantation for soft tissue augmentation. Coleman advocated structural fat grafting for soft tissue rejuvenation of the face and hand with convincing cosmetic results.^{8–10} Most recently, Coleman¹¹ and Spear¹² have reported their clinical experience of fat injection to breasts with encouraging results. Autologous fat grafting to the breast has gained much more attention recently in the plastic surgery community. However, the efficacy and long-term complications of such a procedure for cosmetic breast enhancement have still not been reported and determined in a large series.

For the past 6 years, the authors have been using structural fat grafting for the treatment of various deformities of the breast, including micromastia, ptosis and deformities after removal of silicon implants in 66 patients. All patients had at least 1-year follow up with postoperative sonography, mammography or MRI. The purpose of this study is to evaluate the efficacy and long-term complications of autologous fat grafting to the breast and to study the features of fat necrosis caused by fat transplantation in sonography, mammography or MRI.

Patients and methods

Sixty-six Chinese female patients underwent autologous structural fat grafting to the breast between August 2000 and March 2005 in our institution and were included in this retrospective study. The ages of the patients in this series at the time of the operation were between 19 and 39 years old. The indications for autologous fat grafting to the breast included: (1) correction of contour deformities after removal of silicon implants in 19 patients; (2) cosmetic augmentation of micromastia in 24 patients; and (3) cosmetic augmentation of ptotic breasts in 23 patients.

All 66 patients were enrolled in this study. Physical examination and breast sonography were performed when they returned for follow up to calculate the complication rate of fat necrosis.

Fat grafting to the breast

The fat grafts were harvested from the lower abdomen, trochanter areas, and inner thigh. A two-holed blunt harvesting cannula (3 mm in inner diameter) was connected to a vacuum pump. The fat grafts was aspirated at low negative pressure (–0.5 atm). The fat grafts were then purified after they were washed with some normal saline and spun at a low 600 rpm speed (26g) for 2 min. After centrifugation, the fat grafts from the middle layer were put into 20 cc syringes and then transferred to several 5 ml syringes. The cannula for fat infiltration is a one-holed (3 mm in diameter of the nozzle) blunt cannula. It was connected to the 5 ml syringe for fat infiltration. Two small incisions were made in each breast. Through a periareolar incision, the fat grafts were infiltrated into the subcutaneous tissue of the inner half of the breast. Through an inframammary incision, the fat grafts were infiltrated into the subglandular tissue and the subcutaneous tissue of the lateral half of the breast. Both breasts were then supported with a surgical bra in the first 7 days postoperatively.

In this series, 17 patients each had three instances of fat grafting; 21 patients each had two instances of fat grafting; and 28 patients had only one fat grafting. Between 60 and 120 ml (101 ml on average) of fat was injected into the subcutaneous tissue of the breast and 60–90 ml (73 ml on average) was injected into the subglandular tissue of the breast.

Postoperative follow up

In each patient cosmetic outcome of the breast was assessed at least 12 months after the last fat grafting. The improvement of breast contour deformities was evaluated by three independent plastic surgeons who did not participate in the medical care of the patients and who also did not have any knowledge of what procedures were performed in these patients. The preoperative and postoperative photographs of each patient were evaluated by these three independent plastic surgeons and the degree of contour improvement in the breasts was categorised. The results were graded as significantly improved when the breasts were obviously augmented and the contour defect of the breasts was substantially improved. The results were graded as improved when the breasts were augmented and the contour defect of the breast was improved. The results

were graded as not improved when the breasts were not obviously augmented and the contour defect of the breasts was not improved. The questionnaire used to assess each patient's satisfaction was graded as very satisfied, satisfied or dissatisfied. Clinical data relating to any postoperative complications, especially the development of a breast lump palpated by physical examination, were collected during follow up in all patients.

Imaging follow up

Breast sonography (Du-5, 7–14 MHz, LOGIQ700®, GE) was performed when the patients returned for follow up to calculate the complication rate of fat necrosis. The indication for postoperative mammography (Senographe series GE Healthcare) and MRI (Signa Twinspeed 1.5T, GE Healthcare) was a palpable mass in the breast after fat grafting, sonography demonstrating an anechoic area in the fat graft transplanted region, any other suspicious lesion or at the request of the patients themselves. Breast MRI examination used in this study included T2-weighted, T2-weighted fast spin-echo (FSE), and short inversion time inversion recovery (STIR) sequences in axial plans, and T1-weighted FSE and T2-weighted fat suppression sequences in sagittal planes.

Histopathology

Any patients who developed a significant breast lump within the breast required a surgical exploration and removal of the lump. During the surgery, all palpable lumps

within the breast were removed completely. All biopsy specimens of breast lumps were fixed in 10% formalin solution, sectioned in paraffin and stained with routine haematoxylin and eosin.

Results

Cosmetic outcomes

All patients were followed up from 13 to 61 months, average 37 months, postoperatively. The degree of breast contour was significantly improved in 28 patients (42.4%), improved in 24 patients (36.4%), and not improved in 14 patients (21.2%) as judged by all three independent plastic surgeons. Twenty-seven patients (40.9%) were very satisfied with the results, 26 patients (39.4%) were satisfied with the results, and 13 (19.7%) were unsatisfied with the results. There was a close correlation in the percentage of significant improvement, improvement or no improvement as evaluated by the independent plastic surgeons compared with the percentage of very satisfied, satisfied, or dissatisfied as evaluated by patients themselves (Figs. 1, 2). Tables 1 and 2 are summaries of the outcomes in each category.

Breast sonographic studies

All patients had at least one sonographic scan. Eleven patients were found to have an anechoic area and were

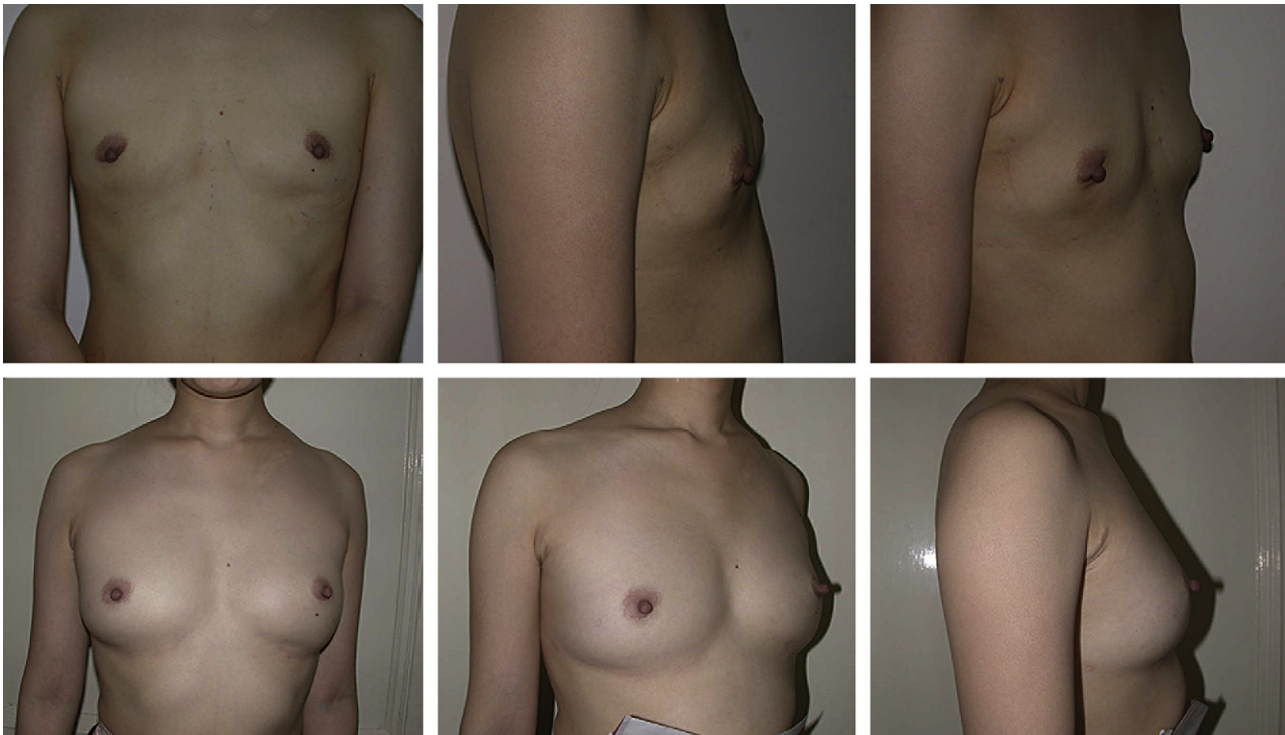


Figure 1 A 27-year-old woman had autologous fat transplantations twice to increase breast volume after the removal of silicon implants. The amount of the fat grafts transplanted was 202 ml in each breast for the first injection, 170 ml for the left breast and 190 ml for the right breast for the second injection. Breast contour was improved significantly as judged by all three evaluators. The patient was also very pleased with the result. Above, preoperative photos. Below, 22 months after the second fat graft.

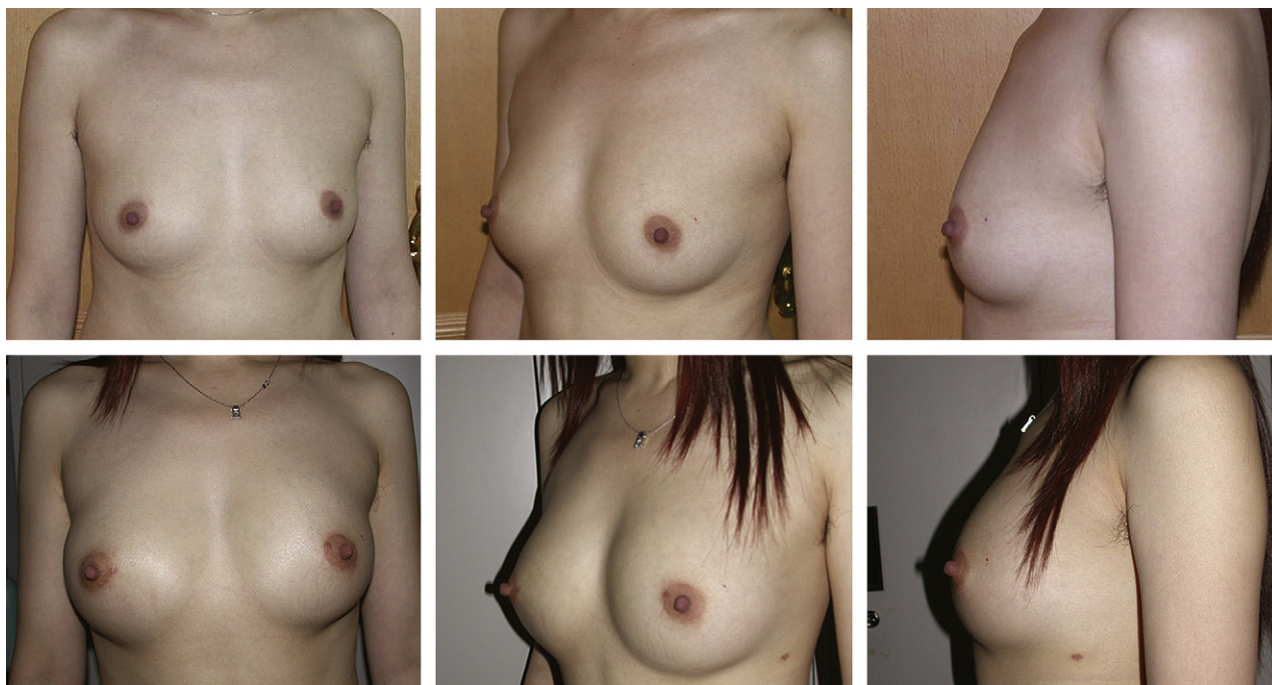


Figure 2 A 23-year-old woman had autologous fat transplantations twice for breast augmentation. The amount of the fat grafts transplanted was 120 ml for the first injection and 140 ml for the second injection. Breast contour was improved significantly as judged by all three evaluators. The patient was also very pleased with the result. Above, preoperative photos. Below, 12 months after the second fat graft.

diagnosed with fat necrosis by sonography. Three of them had a sonographic scan before the procedure (at 1 week, 1, 3, 6 and 12 months after fat grafting to the breast) which showed an isoechoic area in the parenchyma in the subcutaneous and subglandular layer at 1 week and 1 month, but an anechoic area persistently at 12 months postoperatively. The average number of cysts in each breast was 8.9 (range 2 to 36). These cysts had a common feature: a round anechoic mass with a well-defined regular wall.

A total 55 patients had a normal breast ultrasound feature. Nineteen of them had a sonographic scan before the procedure (at 1 week, 1, 3, 6 and 12 months after fat grafting to the breast) which showed an isoechoic area in the parenchyma in the subcutaneous and subglandular layer at 1 week and 1 month and a normal appearance at 12 months postoperatively. In some of those 19 patients anechoic points (2–15 mm in diameter) had appeared at some time between 3 and 6 months after fat grafting.

Mammographic studies

Eleven patients who presented with clinically palpable masses had postoperative mammographies and were

diagnosed with liponecrotic cysts with benign calcification. The average interval between mammography and fat grafting was 23 months (range 12 to 52 months). Mammographic findings of a liponecrotic cyst appeared as an entirely radiolucent round or ellipsoid mass surrounded by a thin or thick fibrous membrane. Calcifications were seen in seven patients an average of 23 months after fat grafting (range 12 to 52 months). This type of calcification appeared to have typical benign features: thin-walled calcifications in oil cysts or coarse irregular calcifications. Clusters of pleomorphic microcalcification that mimic mammographic features of early breast carcinoma were not seen in these patients.

Magnetic resonance imaging (MRI) studies

Nine patients had a postoperative MRI study of the breasts based on the patient's willingness and the cost of an MRI scan. The average interval between imaging and fat grafting was 25.4 months (ranging from 12 to 53 months). All nine patients had breast ultrasound and mammography prior to the subsequent MRI studies.

The findings of the MRI studies confirmed the diagnosis of liponecrotic cysts in the above nine patients, as diagnosed

Table 1 The results of 'significantly improved', 'improved' and 'not improved' in the three categories evaluated by surgeons

Indications	Significantly improved	Improved	Not improved
Removal of silicon implants (19 cases)	13	4	2
Micromastia (24 cases)	8	14	2
Ptotic breasts (23 cases)	7	6	10

Table 2 The results of 'very satisfied', 'satisfied' and 'dissatisfied' in the three categories evaluated by patients

Indications	Very satisfied	Satisfied	Dissatisfied
Removal of silicon implants (19 cases)	14	3	2
Micromastia (24 cases)	8	15	1
Ptotic breasts (23 cases)	5	8	10

by breast sonography and mammography. Necrotic fat is found to have lower signal intensity than the normal fat on T2-weighted, T1-weighted FSE, T2-weighted FSE, T2-weighted fat suppression and STIR sequences in axial and sagittal planes. Signal intensity of fat necrosis decreases on fat suppressed sequence in contrast to the signal intensity of the mammary tissues or breast lumps. Calcifications in some large cysts only are seen on MRI.

Postoperative complications

No immediate serious complications occurred in any patients during or after fat grafting procedures. The main adverse effects were fat necrosis or cyst formation in both breasts which occurred in 11 patients (16.7%). Table 3 is a summary of the results of liponecrotic cysts developed in three categories. Breast lumps were found by physical examination 3.4 months on average (between 2 and 4 months) postoperatively. The lumps averaged 7.1 mm (range 5–25 mm) in diameter and were usually smooth and round. None of the lumps interfered with the final contour of the breast after fat grafting. The breast lumps in these nine patients did not increase in size and the breast lumps in two patients were found to reduce slowly in size.

Two patients who developed fat necrosis within the breast underwent an extirpation of the breast lump, one at 24 months and the other at 51 months after fat grafting. During the surgery, all palpable nodules within the breast were extirpated completely (Fig. 3). No calcification or

newly formed cysts were found in mammograms 1 year after the extirpation.

Pathological findings

All palpable nodules within the breast in these two patients were removed and then analysed. Three types of nodules were identified. One was a pearl-like cyst with a thin wall; the second was ball-like cyst with a thick wall; and the third was an atypical liponecrotic cyst. The diameter of these cysts ranged from 5 to 21 mm.

Histology of a thin-walled cyst revealed a thin layer of collagen capsule containing liquified fat with minimal inflammatory cell reaction. Histology of a thick-walled cyst revealed a thick collagen capsule with moderate inflammatory cell reaction. Certain cysts contained degenerated fatty tissues, and accumulation of multinucleated giant cells was also seen in some specimens. Calcifications appeared only in the inner-layer of the cyst wall. Histology of atypical liponecrotic cysts showed irregular collagen within the capsule with calcifications and significant inflammatory cell infiltration.

Discussion

Autologous fat transplantation has been widely used in facial rejuvenation but its application to the breast has been limited and controversial. Bircoll in 1987 first reported a case of breast augmentation that was performed using autologous fat grafts.¹ He indicated that the major advantage of autologous fat transplantation for cosmetic enhancement of the breast was being able to avoid prostheses and their complications. In more recent case reports, Maillard in 1994 and Castello in 1999^{3,4} reported development of liponecrotic cysts after fat injection to the breasts. The authors cited above believed that the injection of fat grafts to the breast could result in some grade of fat necrosis and inflammation and produce microcalcifications. Recently, Spear et al.¹² reported a good result of fat injections to the breast in 37 patients where fat grafting was done to improve contour deformities in reconstructed

Table 3 The results of liponecrotic cysts developed in three categories

Patients	Indication for surgery	Numbers of cysts in three layers		
		Subcutaneous	Glandular	Subglandular
1	Deformities after removal of silicon implant	1	0	2
2	Deformities after removal of silicon implant	1	0	6
3	Deformities after removal of silicon implant	0	0	6
4	Deformities after removal of silicon implant	0	0	9
5	Correction of ptotic breasts	1	0	1
6	Correction of ptotic breasts	3	0	3
7	Correction of ptotic breasts	2	0	2
8	Correction of ptotic breasts	3	12	21
9	Cosmetic augmentation	1	0	3
10	Cosmetic augmentation	1	0	14
11	Cosmetic augmentation	0	0	6

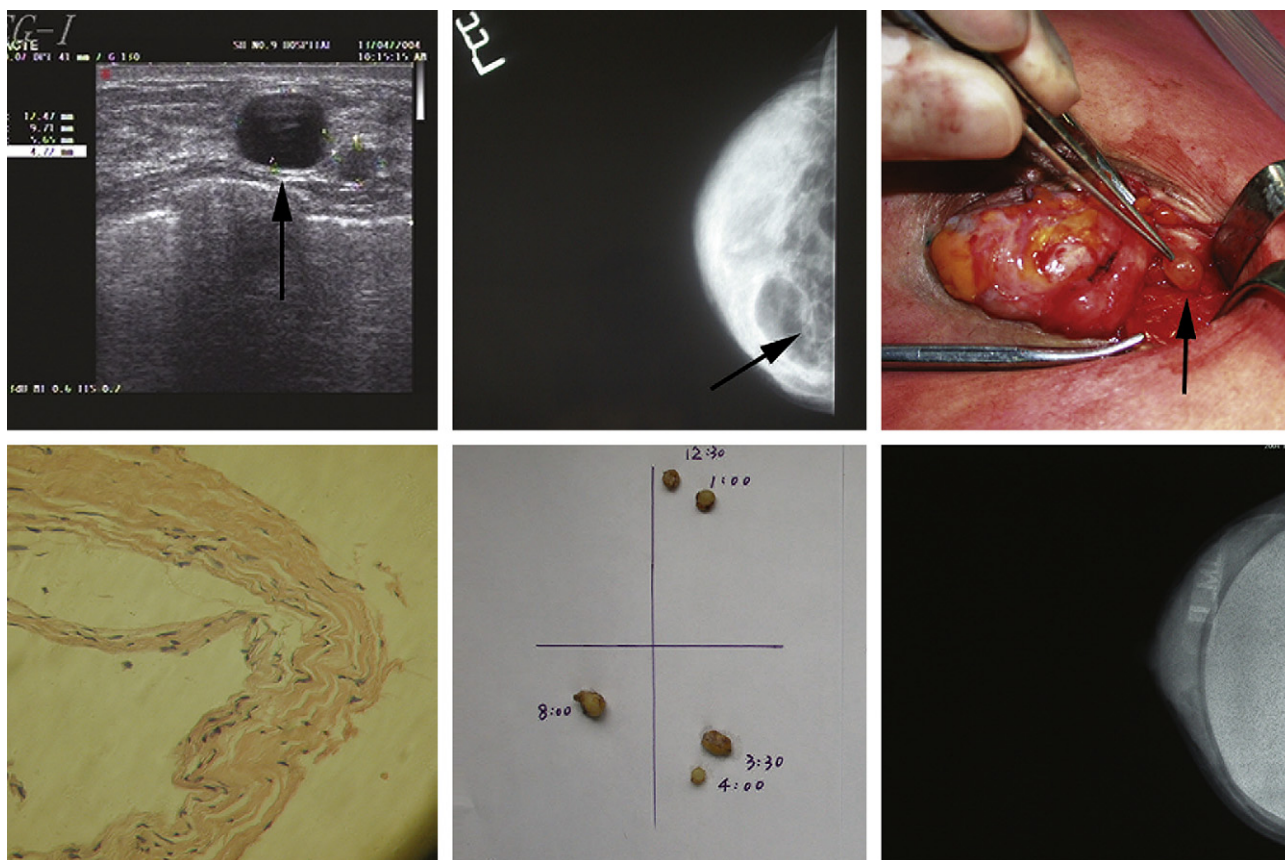


Figure 3 A 43-year-old woman had autologous fat transplantation to her breasts for cosmetic augmentation. Sonography at 47 months showed cysts (arrow) in the subglandular layer of her left breast (above, left). A mammogram at 49 months showed multiple masses in the subglandular layer of her left breast (above, centre). During surgical exploration, a cyst was found and removed completely (above, right). Histology confirmed clinical findings and showed a collagen capsule (below, left). All cysts were removed from the left breast (below, centre). Mammograms 1 year after removal of the cysts and breast augmentation showed no further calcifications (below, right).

breasts. The authors suggest that autologous fat injection in and around reconstructed breasts is a safe technique. However, the efficacy of autologous fat transfer for cosmetic enhancement of the breast has not been determined and justified by any large series studies in the literature. In this report, 66 patients who underwent autologous fat grafting to the breast for cosmetic enhancement were followed for up to 5 years and their cosmetic outcomes, findings from the imaging studies, and any postoperative complications were analysed.

In this series, overall cosmetic improvement was noticed in about 80% of patients as evaluated by independent plastic surgeons or as judged by patients themselves. Patients with breast contour deformities after removal of silicon implants were found to be the best candidates for fat grafting. No cosmetic improvement was noticed in about 20% of patients. The least cosmetic improvement was noted in patients with ptotic breasts. We feel that ptotic breasts always need a large volume of implant materials to rebuild a satisfactory shape, and fat grafting does not meet these requirements very well, especially when compared to breast implant augmentation.

The exact pathogenesis of a liponecrotic cyst developed after fat grafting to the breast is poorly understood. It is

thought to be secondary to an inflammatory response of the host tissue to the fat grafts that become degenerated due to inadequate blood supply. In this series, with an average follow up of 37 months, 11 patients (16.7%) developed one or more liponecrotic cysts after fat grafting to the breast. Most of the liponecrotic cysts were found in the subglandular layer of the breasts. It is possible that fat necrosis is caused by injection of too much fat to one area or by accumulation of injected fat to one area due to the movement of the pectoralis major muscle. How do we minimise the formation of liponecrotic cysts? We agree with Coleman's opinion, i.e. fat should be placed in small aliquots with each pass to maximise the surface area of contact between the grafted fat and the recipient tissue.¹¹ A large surface area of contact between the host tissues with their capillaries and newly grafted tissue promotes nutrition and reduces the number of liponecrotic cysts. So, in our practice, we usually try to keep a small volume (0.2 ml) of fat grafted in one inject-grafting point. In our experience, it is also important that in the early period, about 7 days postoperatively, the breast is in a fixed position using a surgical bra to avoid the local accumulation of grafted fat caused by the movement of the pectoralis major muscle.

Imaging features of liponecrotic cysts and calcification after autologous fat transplantation have not been well documented in the literature except for a few early case series.^{12–16} Sonography appears to be superior to mammography in differentiating a cyst from a solid mass of the breast after fat grafting. Increased echo, anechoic points, and anechoic area with regular walls are important features that should be looked for when diagnosing liponecrotic cysts within the breast. In this series, the calcification was either located in the wall of the oil cysts of the breast or as coarse irregular ones after fat grafting. These are typical benign features of calcifications. Clusters of pleomorphic microcalcifications similar to ductal or amorphous calcifications seen in early breast cancer were not evidenced in any of our patients. Cysts and calcifications in the subcutaneous and subglandular tissues where the fat grafts were placed can be differentiated from benign or malignant lesions within the glandular tissue. In this study, the features of fat necrosis, oil cysts, and calcification on MRI were identified. The presence of decreased signal intensity in the centre of fat necrosis is the key to differentiation of fat necrosis from solid tumour because a cancerous tumour should not contain fat in the centre of the lesion. Signal intensity of fat necrosis decreased on fat-suppressed images in contrast to the intensified signal of the mammary tissue or other breast lumps. Calcifications appear to be a low intensity circle of the signal around a liponecrotic cyst. Any breast lesions can be localised in three dimensions by scanning patients in the magnet with the applied grid. Therefore, MRI is valuable for diagnosis of a liponecrotic cyst.

Postoperative management of liponecrotic cysts in the breast can be done through needle aspiration or surgical extirpation. Once breast sonography identifies a cyst that occurs 1 month postoperatively and its diameters remain the same in the course of the follow up, this may indicate the formation of a cyst secondary to necrotic fat and warrants a needle aspiration in the early postoperative period. However, Maillard³ attempted to aspirate the liquefied fat in the cyst by syringe after 2 months and found more calcifications a few months later in the breast. Possible leakage of the oily content from the cyst that may promote further granulomatous reactions and cysts is a major concern for such an approach.⁵ Open extirpation of the cyst can be a good option. However, more adjacent breast tissue may be excised along with the cyst because of the adherent nature and lack of a true capsule of the cyst.³ In our study, two patients with cyst formation were treated by surgical extirpation. During the operation a capsule of the cyst was found and this was confirmed by histology. No calcification or newly formatted cysts were found 1 year after extirpation. Since calcification was found in the inner layer of the capsule and the cyst was extirpated completely, this

may explain why no more calcifications were seen during further follow up.

In conclusion, autologous fat grafting to the breast can be a useful procedure for cosmetic enhancement in many patients who desire such a procedure. Patients with breast contour deformities after removal of silicon implants were found to be the best candidates for fat grafting. The primary long-term complication is the formation of liponecrotic cysts which have characteristically benign appearances in sonography, mammography or MRI.

References

1. Bircoll M. Cosmetic breast augmentation utilizing autologous fat and liposuction techniques. *Plast Reconstr Surg* 1987;**79**: 267–71.
2. Mandrekas AD, Zambacos GJ, Kittas C. Cyst formation after fat injection. *Plast Reconstr Surg* 1998;**102**:1708–9.
3. Maillard GF. Liponecrotic cysts after augmentation mammoplasty with fat injections. *Aesthetic Plast Surg* 1994;**18**: 405–6.
4. Castello JR, Barros J, Vazquez R. Giant liponecrotic pseudocyst after breast augmentation by fat injection. *Plast Reconstr Surg* 1999;**103**:291–3.
5. Har-Shai Y, Lindenbaum E, Ben-Itzhak O, et al. Large liponecrotic pseudocyst formation following cheek augmentation by fat injection. *Aesthetic Plast Surg* 1996;**20**:417–9.
6. Carpaneda CA. Study of aspirated adipose tissue. *Aesthetic Plast Surg* 1996;**20**:399–402.
7. Carpaneda CA, Ribeirrom MT. Study of the histologic alterations and viability of the adipose graft in humans. *Aesthetic Plast Surg* 1993;**17**:43–7.
8. Coleman SR. Structural fat grafts: the ideal filler? *Clin Plast Surg* 2001;**28**:111–9.
9. Coleman SR. Hand rejuvenation with structural fat grafting. *Plast Reconstr Surg* 2002;**110**:1731–44.
10. Colema SR. Structural fat grafting: more than a permanent filler. *Plast Reconstr Surg* 2006;**118**(35):108S–20.
11. Coleman SR, Saboeiro Alesia P. Fat grafting to the breast revisited: safety and efficacy. *Plast Reconstr Surg* 2007;**119**(3): 775–85.
12. Spear SL, Wilson HB, Lockwood MD. Fat injection to correct contour deformities in the reconstructed breast. *Plastic Reconstr Surg* 2005;**116**:1300–5.
13. Kroll SS, Gherardini G, Martin JE, et al. Fat necrosis in free and pedicled TRAM flaps. *Plast Reconstr Surg* 1998;**102**:1502–7.
14. Orel SG. MR imaging of the breast for the detection, diagnosis, and staging of breast cancer. *Radiology* 2001;**220**:13–30.
15. Devon RK, Rosen MA, Mies C, et al. Breast reconstruction with a transverse rectus abdominis myocutaneous flap: spectrum of normal and abnormal MR imaging findings. *RadioGraphics* 2004;**24**:1287–99.
16. Pulagam SR, Poulton T, Mamounas E. Long-term clinical and radiologic results with autologous fat transplantation for breast augmentation: case reports and review of the literature. *Breast J* 2006;**12**:63–5.